

Multiple pathways to dissipate body heat excess and the infrared thermography effectiveness



João Batista Freire Souza-Junior^{a,c*}  | João Paulo Araújo Fernandes de Queiroz^{b,c} 

^aDepartment of Animal Science, Universidade Federal do Ceará, Fortaleza, CE, Brazil.

^bDepartment of Veterinary Medicine, Universidade Federal de Roraima, Boa Vista, RR, Brazil.

^cLaboratory of Animal Biometeorology and Environmental Biophysics, Universidade Federal Rural do Semi-Árido, Mossoró, RN, Brazil.

*Corresponding author: souza.jr@ufersa.edu.br

Keywords: birds, heat stress, mammals, thermal biology, thermal imaging, thermoregulation

Background

The world has been undergoing several natural transformations in recent centuries; for the most part, these changes are driven by anthropic actions. It is already common knowledge in the scientific community that climate change has been observed and that, mainly, global warming seems to be an imminent event, with highlights on forecasts of atmospheric temperature average increase in the coming decades.

Under thermally stressful conditions, animals receive a significant heat load from the environment. Regardless of the animal species, body heat excess brings physiological damage that can, in extreme cases, be irreversible. In these thermal challenge situations – here, we refer only to heat – the animals need to dissipate the excess heat from the environment. In this sense, body surface regions evolved to play a critical role in the thermal balance acquisition between animals and the environment, even being unattainable in geographical areas with hot climates (Souza Jr et al 2018).

In this scenario, specific body regions specialize in dissipating heat under heat stress by increasing peripheral blood circulation, the so-called thermal windows (Codde et al 2016; Van De Ven et al 2016; Thompson et al 2017). On the other hand, under cold stress conditions, peripheral vasoconstriction is observed, as the thermophysiological objective is different: body heat conservation. Superficially, thermal windows are characterized by the absence or presence of few hairs (mammals) or feathers (birds). It is well known that hair and feathers play as resistance to heat transfer from the body to the environment. In some cases, an air layer is still formed between the hairs (or feathers), reducing the system's thermal conductivity and causing less heat dissipation.

In the thermal window concept, which has already been well established and explained earlier, when it is hot, "the window opens", indicating peripheral vasodilation; when it is cold, "the window closes", as a representation of peripheral vasoconstriction. However, some specific animals

have body surface regions without a layer of feathers (or hair) and are compromised with sensible heat loss and, unlike thermal windows, do not "close". We call these body areas of thermolysis sites, and we exemplify these throughout this editorial.

One of the ways to body surface temperature measuring is through the use of infrared thermography (IRT). As a non-invasive technique, it becomes valuable in measuring the animals' body temperature, especially in field conditions (Tattersall 2016). This topic has recently been addressed in review articles published in our journal (Bertoni et al 2020; Mota-Rojas et al 2021). As there is no contact with the animal to be studied, the IRT presents itself as an exciting tool for collecting animal physiological data. With this technology, the thermal images (or thermograms) allow the body surface temperature mapping, being a facilitator in the forecast of sensible heat exchanges (Souza-Junior et al 2019). Recent findings on how some animals (farm and wild) use their body surface regions to dissipate excess heat determined with the infrared thermography application are briefly discussed below.

The case of rodents from the Brazilian hot-dry region

Among the wild species, we highlighted the Spix's yellow-toothed cavy (*Galea spixii*) and the red-rumped agouti (*Dasyprocta leporina*), two rodents from the Brazilian hot-dry region (Figure 1). The main thermal windows were: periocular and vibrissae regions, for Spix's yellow-toothed cavies; forelimbs, for red-rumped agoutis; ears, for both rodents. The periocular surfaces were those with greater participation in thermal exchanges by radiation. The high temperature in these regions is associated with a decrease in resistance to heat transfer from the epidermis due to the absence of hair on the eyelid edges and commissures, combined with a short coat covering the region. Vibrissae are part of the sensory system of these terrestrial and fossorial rodents. These hair-covered areas have a vasomotor mechanism that allows the animal to exert some control over temperature, maintaining tactile sensitivity in different



environmental conditions (Queiroz et al 2020). Concerning the forelimbs of the red-rumped agoutis, the low insulation, the pigmented epidermis, and the long metatarsus (region visible due to the animal remaining seated during the thermal image recording) make them an important site of thermolysis (Queiroz et al 2019).

The primary function of the ears in mammals is to increase auditory acuity. Its thermoregulatory function is secondary; however, no less important for many species. These appendages have a high area/volume ratio and extensive vascular network, facilitating heat transfer by non-evaporative pathway. Both for Spix's yellow-toothed cavy and red-rumped agoutis, the membranous nature, low hair density, and rich subcutaneous vascularization make ears important sites of radiation thermolysis. Thermograms revealed that the surface temperature was higher in areas

close to the external acoustic meatus, gradually decreasing up to the edges of the external ears (Queiroz et al 2019; Queiroz et al 2020).

Despite the significant participation in thermal exchanges by radiation in cavy and agoutis, ocular surfaces are not considered thermal windows due to the complete absence of thermal insulation. The temperature in this body region remains high and constant because these are highly vascularized sensory organs. Such characteristics allow the ocular temperature to be used as an indicator of the physiological and/or metabolic state under controlled environmental conditions. However, under field conditions, this physiological variable must be used cautiously and accompanied by thermal environment monitoring (Queiroz et al 2020; Queiroz et al 2020).

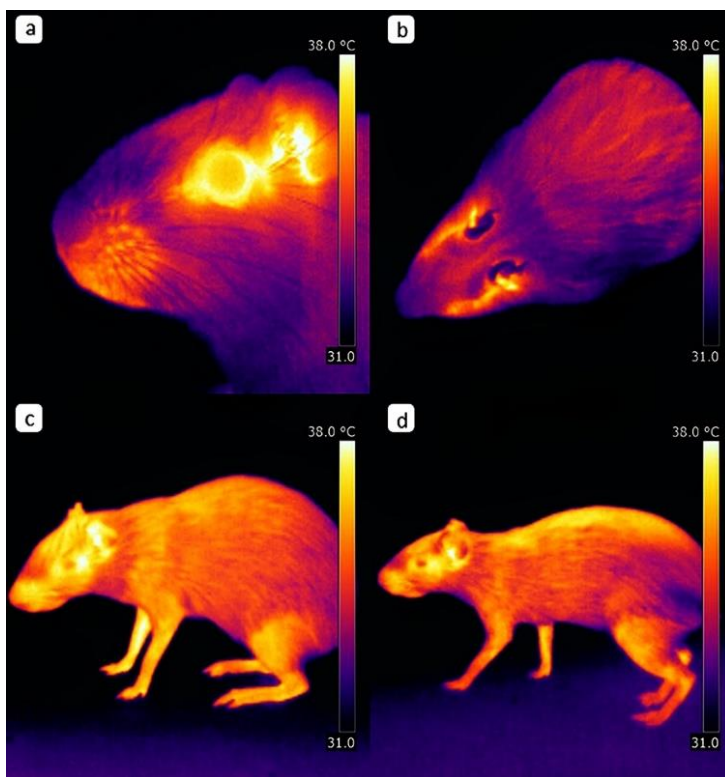


Figure 1 Side view of the head (a) and the top view of the body (b) of Spix's yellow-toothed cavy. Side view of red-rumped agouti in sitting (c) and standing postures (d).

The case of the naked-neck chickens

Productive losses in poultry farming are commonly generated nowadays. The clear reason for this is the thermal challenge arising from heat stress, which has become a barrier to efficient poultry production (Saeed et al 2019). In production systems where it is impossible to control the environment through thermal conditioning fully, the use of birds with the Na gene (naked neck) appears as an alternative (Souza Jr et al 2015). Decreased feather mass (when compared to normally feathered breeds) ensures greater adaptation to high temperatures (Sharifi et al 2010), as this region of the body acts as a thermolysis site, specializing in sensible heat dissipation (Souza-Junior et al 2019). As most of the birds' body surface is covered with feathers, which is of considerable importance in environments characterized by

low temperatures, any reduction in the feathers amount benefits the fight that birds have against heat stress. This was observed in laying hens raised in a hot environment, the Brazilian semi-arid.

Souza-Junior et al (2019) estimated sensible heat loss (*SHL*) through infrared thermography and equations using biophysical principles. The surface temperature of the area covered by feathers (body trunk; Figure 2c) was close to the ambient temperature. In this case, the *SHL* was incipient, as this temperature differential drives sensible heat transfer. On the other hand, *SHL* on the neck and face (Figures 2a and 2b) showed the highest values, proving to be efficient thermolysis sites for this hen breed. In this same study, the legs (Figure 2d) did not behave as thermal windows, differently from what was expected. These highly

vascularized and specialized body regions for heat loss did not show significant variation within the temperature range (24-31 °C) and were less efficient than the other featherless regions. The results would probably have been different if the

birds had been subjected to temperatures lower than 24 °C and higher than 31 °C, which is a superior thermal challenge in the latter case.




Figure 2 Thermograms of naked-neck birds in a hot environment. Highlight on the face and neck of cock (a) and hen (b); in (c), the thermal profile of the hen, showing the body trunk covered with feathers; highlight on legs (d); chicks are showing different behaviors, thermal comfort (e) and cold stress (f).

Regarding necked-neck chicks, some other points should be taken into consideration. At this production system stage, an artificial heating source is mandatory. In semi-intensive systems, lamps warm up the chicks in the first four weeks of life. Under these conditions, the thermogenic heat that would be dissipated to the environment through the thermolysis sites is compensated by artificial heating (Figure 2e); if this heating is not efficient, chicks can use behavioral strategies to decrease the area without feathers exposed to the environment (Figure 2f; Souza-Junior, unpublished data).

Conclusions and perspectives

In the studies with rodents and necked neck birds approach in this editorial, the thermal imaging utilization for body surface temperature mapping proved efficient in identifying thermolysis and thermal windows beyond being a useful tool in sensible heat loss estimating.

Despite the valuable recommendations and cautions to be taken for using infrared thermography and the thermal imaging acquisition suggested by Leite et al (2022), we

defend the studies with animals in their husbandry natural conditions, either in intensive systems or animals in the wild. We recognize that limitations are found and that methodologies still need to be advanced to produce results that are more consistent with the reality of productive systems.

Ethical considerations

Not applicable.

Conflict of Interest

The authors declare no conflict of interest.

Funding

Not applicable.

References

Bertoni A, Mota-Rojas D, Álvarez-Macias A, Mora-Medina P, Guerrero-Legarreta I, Morales-Canela A, Gómez-Prado J, José-Pérez N, Martínez-Burnes J (2020) Scientific findings related to changes in vascular



- microcirculation using infrared thermography in the river buffalo. *Journal of Animal Behaviour and Biometeorology* 8:288-297.
- Codde SA, Allen SG, Houser DS, Crocker DE (2016) Effects of environmental variables on surface temperature of breeding adult female northern elephant seals, *Mirounga angustirostris*, and pups. *Journal of Thermal Biology* 61:98-105
- Leite RF, Rodrigues LA, Freitas Neto MA, Nogueira FRB, Lima JDS, Souza BB, Miranda Neto EG (2022) Principles and cautions in the infrared thermography application in sheep. *Multidisciplinary Reviews* 5:e2022001.
- Mota-Rojas D, Napolitano F, Braghieri A, Guerrero-Legarreta I, Bertoni A, Martínez-Burnes J, Cruz-Monterrosa R, Gómez J, Ramírez-Bribiesca E, Barrios-García H, José N, Álvarez A, Mora-Medina P, Orihuela A (2021) Thermal biology in river buffalo in the humid tropics: neurophysiological and behavioral responses assessed by infrared thermography. *Journal of Animal Behaviour and Biometeorology* 9:2103.
- Queiroz JPAF, Souza Jr JBF, Oliveira VRM, Castelo TS, Dantas MRT, Costa LLM, Oliveira MF (2019) Sensible heat transfer and thermal windows in *Dasyprocta leporina* (Mammalia, Rodentia). *Biological Rhythm Research* 50:232-244.
- Queiroz JPAF, Souza Jr JBF, Oliveira VRM, Costa LLM, Oliveira MF (2020) How does Spix's yellow-toothed cavy (*Galea spixii* Wagler, 1831) face the thermal challenges of the Brazilian tropical dry forest? *Journal of Thermal Biology* 88:102525.
- Saeed M, Abbas G, Alagawany M, Kamboh AA, El-Hack AEB, Khafaga AF, Chao S (2019) Heat stress management in poultry farms: a comprehensive overview. *Journal of Thermal Biology* 84:414-425.
- Sharifi AR, Horst P, Simianer H (2010) The effect of naked neck gene and ambient temperature and their interaction on reproductive traits of heavy broiler dams. *Poultry Science* 89:1360-1371.
- Souza Jr JBF, Oliveira VRM, Arruda AMV, Silva AM, Costa LLM (2015) The relationship between corn particle size and thermoregulation of laying hens in an equatorial semi-arid environment. *International Journal of Biometeorology* 59:121-125.
- Souza Jr JBF, Queiroz JPAF, Santos VJS, Dantas MRT, Lima RN, Lima PO, Costa LLM (2018) Cutaneous evaporative thermolysis and hair coat surface temperature of calves evaluated with the aid of a gas analyzer and infrared thermography. *Computers and Electronics in Agriculture* 154:222-226.
- Souza-Junior JBF, El-Sabroun K, Arruda AMV, Costa LLM (2019) Estimating sensible heat loss in laying hens through thermal imaging. *Computers and Electronics in Agriculture* 166:105038.
- Tattersall GJ (2016) Infrared thermography: A non-invasive window into thermal physiology. *Comparative Biochemistry and Physiology Part A: Molecular & Integrative Physiology* 202:78-98.
- Thompson CL, Scheidel C, Glander KE, Williams SH, Vinyard CJ (2017) An assessment of skin temperature gradients in a tropical primate using infrared thermography and subcutaneous implants. *Journal of Thermal Biology* 63:49-57.
- Van De Ven TMFN, Martin RO, Vink TJ, McKechnie AE, Cunningham SJ (2016) Regulation of heat exchange across the hornbill beak: functional similarities with toucans? *Plos One* 11:e0154768.